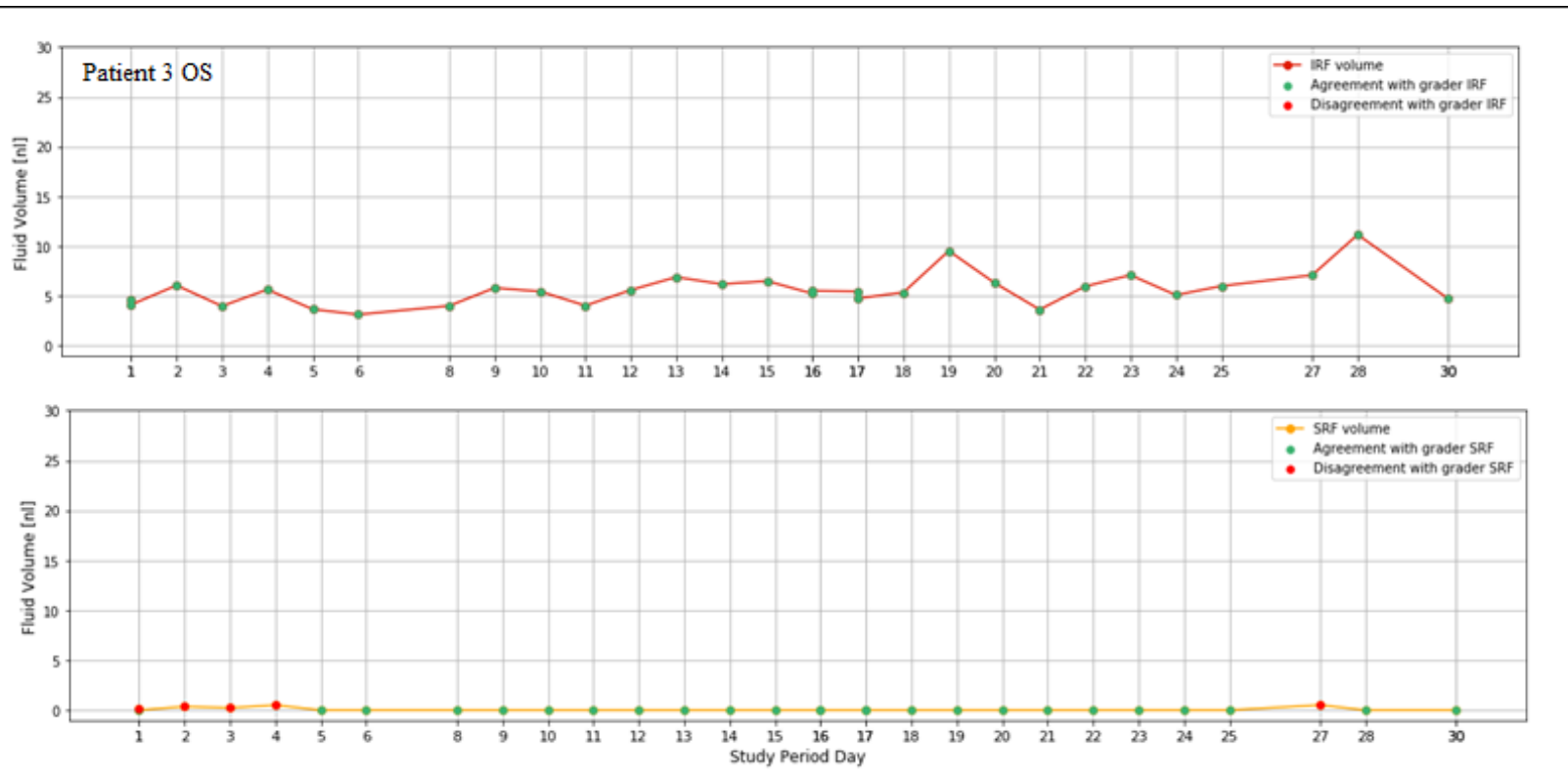


Supplementary Figure 5. Retinal fluid volume-time curves for study eye 3 OS

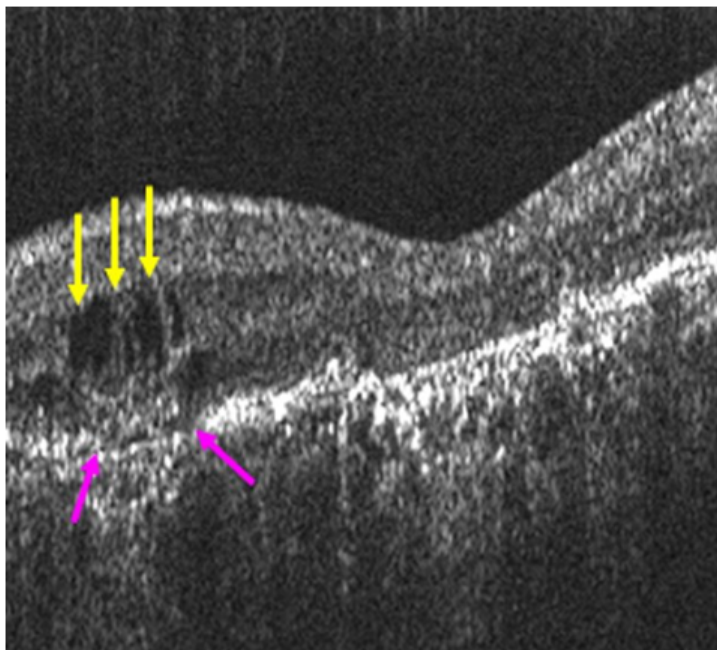
The eye had both neovascular disease and intraretinal degenerative cysts near an area of complete retinal pigment epithelial and outer retinal atrophy (cRORA).

A. The eye received an injection of bevacizumab 6 weeks prior to the beginning of the study period. Daily self-imaging revealed persistent intraretinal cysts with a very small intraretinal fluid (IRF) volume of approximately 5 nl throughout the study period.

B. Home OCT images at baseline (left) and day 25 (right) showed degenerative cysts as hyporeflective intraretinal areas (yellow arrows), with nearby cRORA (pink arrows).



Left



Right

